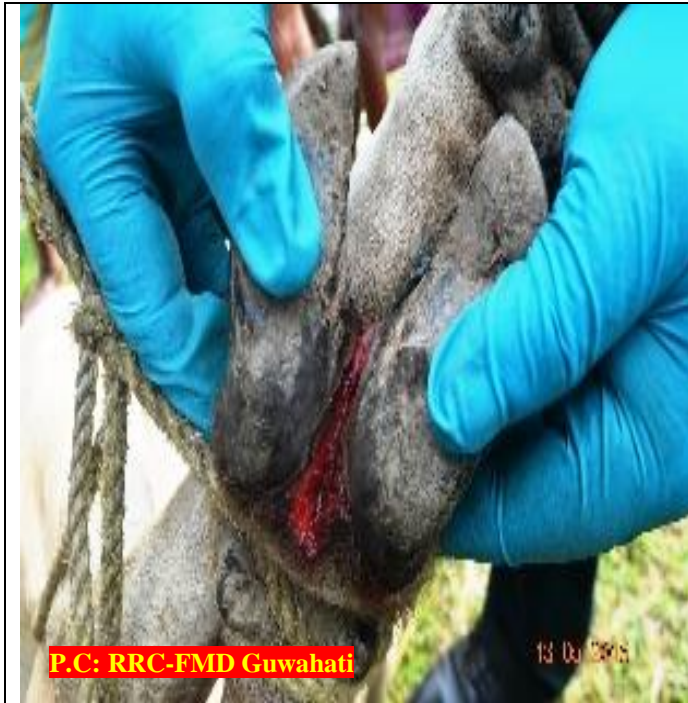

CATTLE AFFECTED WITH FMD

How To Diagnose:

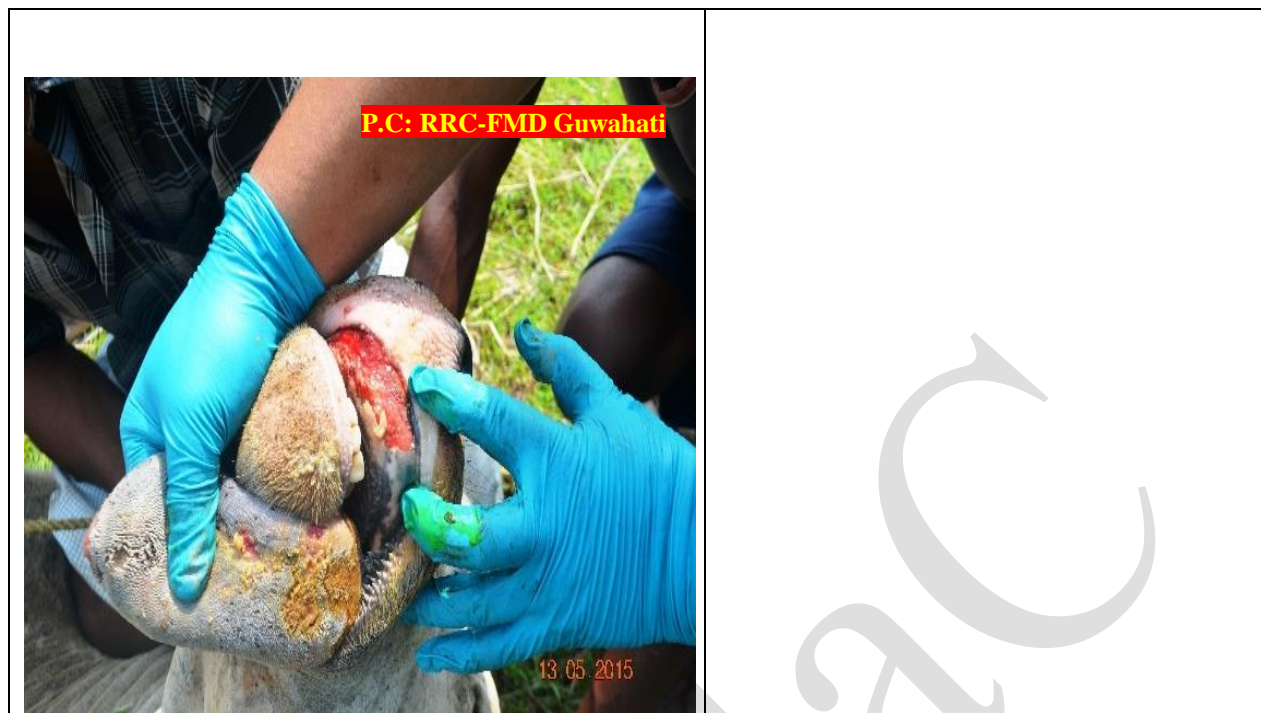


The junction between the hoofs is affected and leads to sloughing of the epithelium.



In severe cases, hoof crack open and secondary infection (bacterial) sets in.

Lameness aggravated by infestation of maggots in the open wounds occur.



Whom To Contact:

- Local Veterinarian Officer/ Field Assistant.
- ADMaC, Core Lab- I , AAU, Khanapara
 - ◆ Dr. S. K. Das, PI, ADMaC.
E mail – drskdas53@gmail.com, Mob No. 09435014705
 - ◆ Dr. N.N.Barman, Co PI, ADMaC.
E mail – nnbarman@gmail.com, Mob No.0943555 8788

What will you do:

- Clean the floor with phenol and potash solution properly.
- Separate the affected ones from the healthy animals. Dispose discharges regularly.
- Inform nearest Veterinary Doctor/Field Assistant.
- Send appropriate samples through Veterinary Doctor/Field Assistant to the nearest diagnostic laboratory/ ADMaC Core Lab-I, Khanapara for confirmation of the disease.
- Maintain the personal hygiene and keep farm surrounding clean.