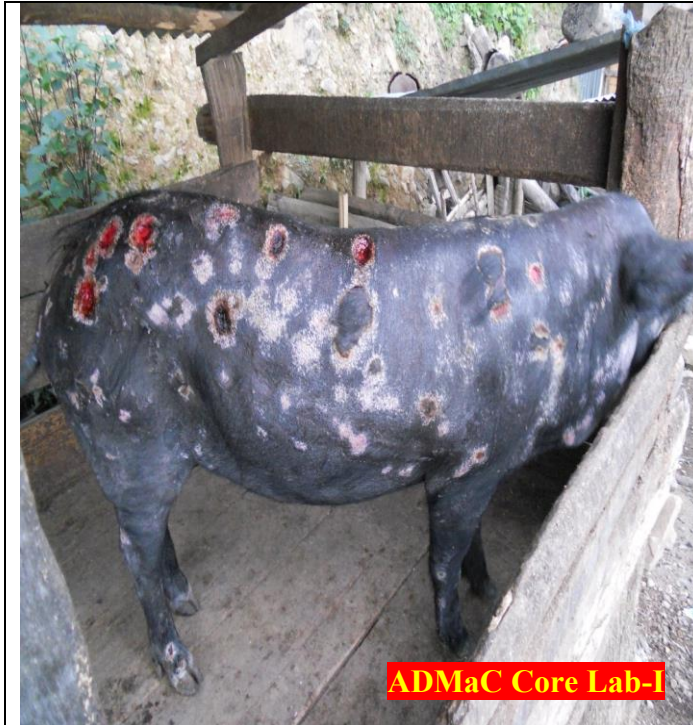
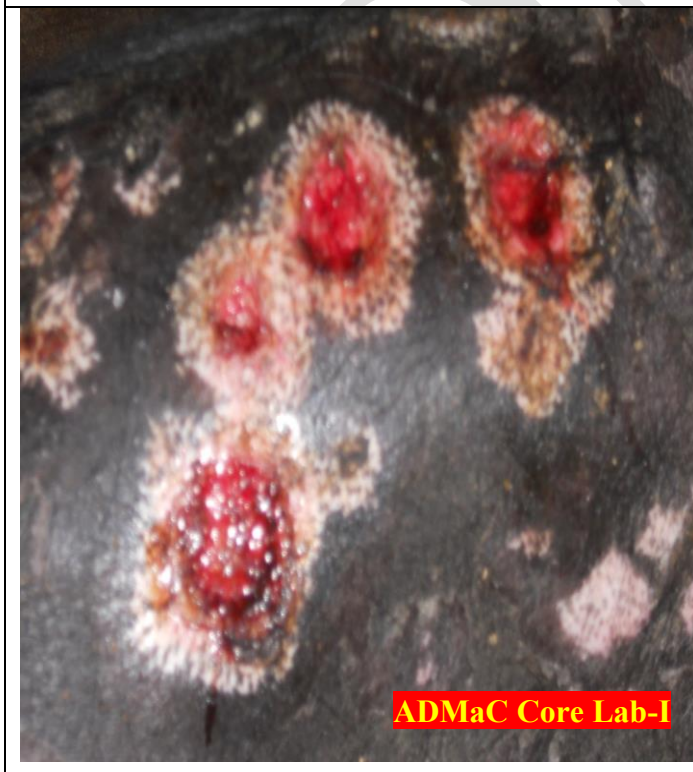

PIG AFFECTED WITH ERYSIPELAS

How To Diagnose:



Skin lesions may vary from red to purple widespread discoloration of the ears, snout, and abdomen to diamond shaped skin lesions almost anywhere on the body.



Characteristic pathognomonic diamond skin lesions on the body surface of infected pig.



Necrosis and separation of large areas of skin can occur, but more commonly, the tips of the ears and tail may become necrotic and slough.

Whom To Contact:

- Local Veterinary Doctor and Field Assistant.
- ADMaC, Core Lab- I, Khanapara
 - ◆ Dr. S. K. Das, PI, ADMaC.
E mail – drskdas53@gmail.com, Mob No.09435014705
 - ◆ Dr. N.N.Barman, Co PI, ADMaC.
E mail – nnbarman@gmail.com, Mob No.0943555 8788

What will you do:

- Lock your farm and do not allow pigs to move in and out.
- Separate the affected ones from the healthy.
- Stop selling pork, piglets in the market.
- Inform nearest Veterinary Doctor/Field Assistant.
- Send appropriate samples through Veterinary Doctor/Field Assistant to the nearest diagnostic laboratory/ ADMaC Core Lab-I, Khanapara for diagnosis of the disease.
- Bury dead pigs in 5 to 6 feet deep pit putting sufficient amount of common salt/lime or washing soda.
- Spray regularly with 4% washing soda or 4% phenol in the farm surrounding and floor of the pig house.
- Hotel/ household foods should be boiled before providing to pigs.

- Regularly vaccinate the herd as per schedule. Vaccine will be available at-
 - Veterinary Biologicals Animal Husbandry and Veterinary Department Guwahati, Khanapara.
 - College of Veterinary Science, Khanapara, Guwahati.

ADMaC