

AVIAN POX

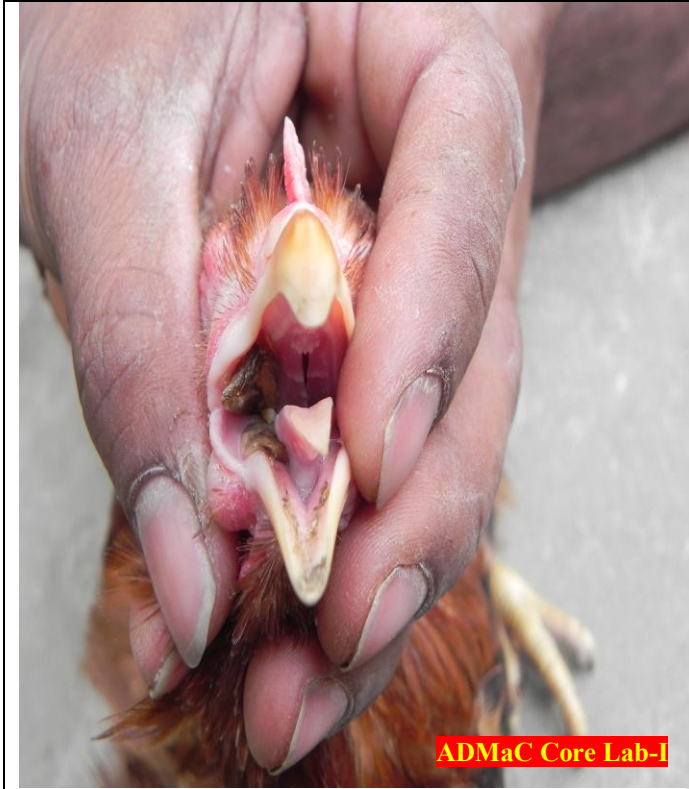
How To Diagnose:



Pock like lesions appear chiefly around the peri-orbital areas, nares, digits and conjunctiva.



In severe cases, secondary bacterial infection causes rupture of the vesicle and pus formation.



Birds are unable to eat and drink and in severe cases, mortalities are also recorded.



Usually, squabs are affected during nestling stage.

Whom To Contact:

- Local Veterinarian Doctor and Field Assistant.
- Core Lab- I
 - ◆ Dr. S. K. Das, PI, ADMaC.
E mail – drskdas53@gmail.com, Mob No. 09435014705
 - ◆ Dr. N.N.Barman, Co PI, ADMaC.
E mail – nnbarman@gmail.com, Mob No.0943555 8788

What will you do:

- Isolate the affected ones from the healthy animals.
- Inform nearest Veterinary Doctor/Field Assistant.
- Send appropriate samples through Veterinary Doctor/Field Assistant to the nearest diagnostic laboratory/ ADMaC Core Lab-I, Khanapara for confirmation of the disease.
- Maintain the personal hygiene and keep farm surrounding clean.